International Journal of Research in Health and Allied Sciences

Journal home page: www.ijrhas.com

ISSN 2455-7803 Index Copernicus value 2016 = 68.10

Original Article

A Retrospective Study of 12 cases of Tuberculosis of Hip Bone in Children

Krishna Kharel

Department of Orthopaedics, Devdaha Medical College and Research Institute Devdaha, Nepal

***ABSTRACT*:**
Background: The most common form of articular tuberculosis is spondylitis followed by arthritis of weight bearing joints especially knee and hip. The present study was conducted to study cases of tuberculosis of hips in children's. **Materials & Methods:** 12 patients of both genders with history of hip tuberculosis were included. The diagnosis was done with the help of histopathology and clinic-radiological basis. Shanmugasundaram radiological classification was used in this study. **Results:** Out of 12 patients, males were 5 and females were 7. The difference was non- significant (P-0.13). Right side was involved in 8 cases and left side was seen in 4 cases. The difference was significant (P<0.05). Radio graphically, 3 were normal, 4 were travelling, 2 were dislocating and 1 was atrophic. The difference was significant (P<0.05). Post- treatment findings were normal in 7 cases, atrophic in 1 case, protrusion acetabuli in 1 case, perthes in 1 case and mortar pestle in 2 cases. The difference was significant (P<0.05). Result was excellent (40%), good (22%), fair (27%) and poor (11%). The difference was significant (P<0.05). **Conclusion:** Tuberculosis of hip is not uncommon among children. Clinical and radiological diagnosis along with histopathological findings is sufficient to reach the final diagnosis.
Key words: Atrophic, Hip, Tuberculosis.

Received: 2 December 2017 Revised: 18 December 2017 Accepted: 20 December 2017

Corresponding author: Dr. Krishna Kharel, Department of Orthopaedics, Devdaha Medical College and Research Institute Devdaha, Nepal

This article may be cited as: Kharel K. A Retrospective Study of 12 cases of Tuberculosis of Hip Bone in Children. Int J Res Health Allied Sci 2018;4(1):1-3.

INTRODUCTION

The most common form of articular tuberculosis is spondylitis followed by arthritis of weight bearing joints (especially knee and hip). The spine is the most common site followed by the hip joint which constitutes approximately 15% of all cases. Tuberculosis can affect any bone, but most commonly it attacks the spine and weight-bearing joints. Tuberculous osteomyelitis, or bone infection, causes constant pain in the bone itself and can cause complications in nearby tissues, such as carpal tunnel syndrome if the wrist is affected.[1]

Pott disease or Pott's disease is a form of tuberculosis that occurs outside the lungs whereby disease is seen in the vertebrae. Tuberculosis can affect several tissues outside of the lungs including the spine, a kind of tuberculous arthritis of the intervertebral joints. The occurrence of additional symptoms depends on where the disease has spread beyond the chest and lungs. For example, if TB spreads to the lymph nodes, it can cause swollen glands at the sides of the neck or under the arms. When TB spreads to the bones and joints, it can cause pain and swelling of the knee or hip.[2]

Before the advent of modern antitubercular drugs, the treatment of tuberculosis hip was expectant. Arthrodesis was considered the ultimate aim for tubercular arthritis of hip as it was believed that mobility will reactivate the tubercular bacteria. Gradually, with availability of antitubercular chemotherapy, concept of regaining or restoring mobility in the diseased hip came into vogue. The management of tuberculosis hip in children aims at identifying the disease in predestruction stage, instituting multidrug antitubercular chemotherapy combined with necessary surgical interventions and restoring hip function to normal/near normal as possible.[3]

TB disease can be treated by taking several drugs for 6 to 9 months. There are 10 drugs currently approved by the U.S. Food and Drug Administration (FDA) for treating TB. Of the approved drugs, the first-line anti-TB agents that form the core of treatment regimens are: isoniazid (INH), rifampicin, streptomucin, ethambutol,

pyrozinamide etc.[4] The present study was conducted to study cases of tuberculosis of hips in children's.

MATERIALS & METHODS

The present study included 12 patients of both genders with history of hip tuberculosis. All were informed regarding the study and written consent was obtained. Ethical clearance was taken from institutional ethical committee.

The diagnosis was done with the help of histopathology and clinic-radiological basis. The histopathological criteria for diagnosis were the presence of chronic granulomatous inflammation with caseation and/or presence of epitheloid cells and lymphocyte configuration of tubercle. The clinical criteria were pain, limping, deformity and fullness around the hip joint, restriction of movements, and presence of abscess with or without discharging sinus, limb shortenings.

Extraoral radiographs of hip bone was taken and osteopenia, diminution in joint space, erosions of articular margins, lytic lesions, pathological fractures, subluxations or dislocations were considered for diagnosis. Shanmugasundaram[5] radiological classification was used in this study. There were some hip involvements which cannot be classified based on these conventional types. Three different patterns were observed in the unclassified type - triradiate, pseudarthrosis coxae and ankylosed type. Results thus obtained were subjected to statistical analysis. P value less than 0.05 was considered significant.

RESULTS

Table I shows that out of 12 patients, males were 5 and females were 7. The difference was non- significant (P-0.13).

Table I Distribution of patients

	Total- 12	
Male	Female	P value
5	7	0.13

Graph I Side of involvement

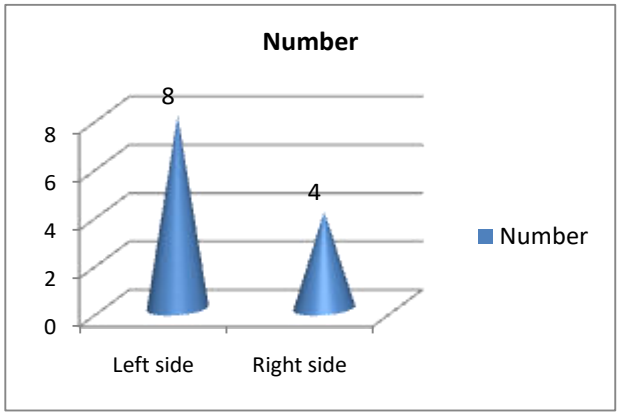

Graph I shows that right side was involved in 8 cases and left side was seen in 4 cases. The difference was significant (P<0.05). Graph II shows that radio graphically, 3 were normal, 4 were travelling, 2 were dislocating and 1 was atrophic. The difference was significant (P<0.05).

Graph II Pre- treatment radiographic findings

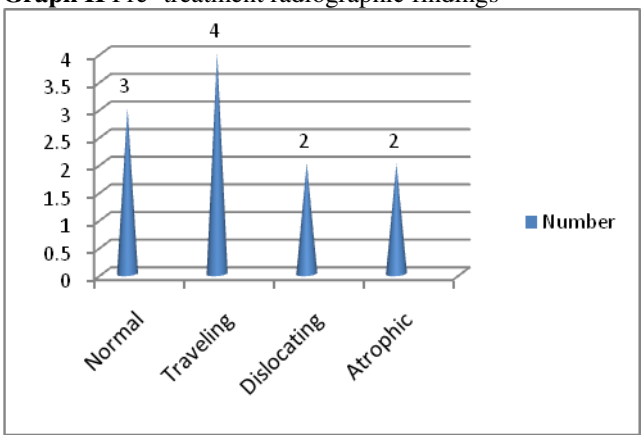

Graph III Post- treatment radiographic findings

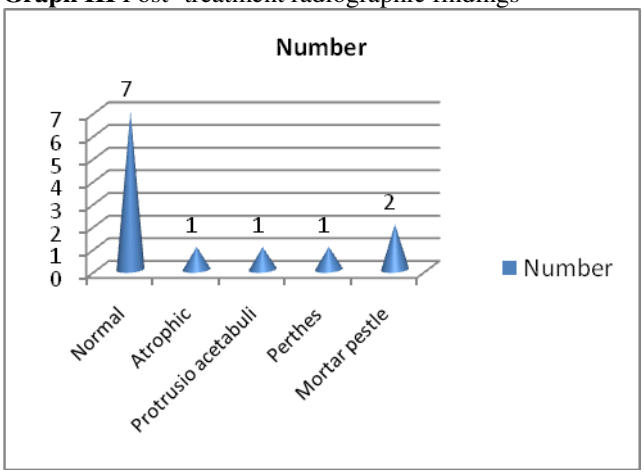

Graph IV Results of treatment as per moon's criteria

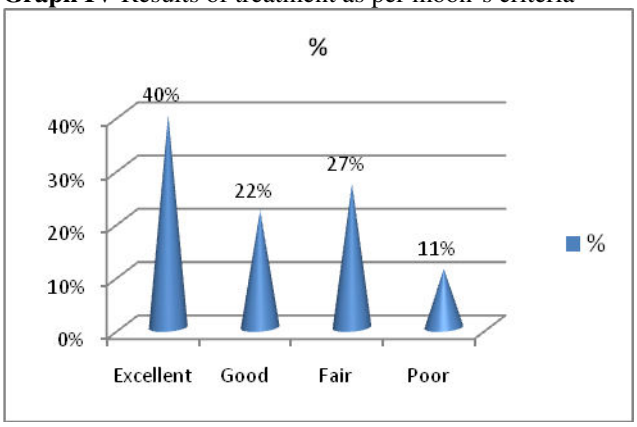

Graph III shows that post- treatment findings were normal in 7 cases, atrophic in 1 case, protrusion acetabuli in 1 case, perthes in 1 case and mortar pestle in 2 cases. The difference was significant (P<0.05). Graph IV shows that result was excellent (40%), good (22%), fair (27%) and poor (11%). The difference was significant (P<0.05).

DISCUSSION

Tuberculosis (TB) of hip presents significant clinical problems, though undoubtedly it has become rarer than before. The disease once established in the hip leads to progressive destruction of the joint if untreated at an early stage, and may even proceed to pathological dislocation. The pain, loss of movement, and progressive development of deformity results in loss of function of the affected hip. Subluxated or dislocated hips following infection are difficult to be managed to obtain a stable, mobile, congruous, and concentric joint. Generally, such hips with advanced lesion luxate further and/or finally result in osteoarthritic or ankylosis even after disease healing. Skeletal tuberculosis in the pediatric age group is uncommon with a reported incidence of 5-6% of pediatric extra pulmonary cases.[6]

Hip tuberculosis constitutes nearly 20% of all cases of skeletal tuberculosis. The exact proportion of tubercular hip affection in the pediatric age group is not known but the disease is rare. There is a paucity of literature regarding osteoarticular tuberculosis of hip in children with only few dedicated series available in recent indexed English literature and probably none from the Indian subcontinent. Thus, the clinic-radiological course in osteoarticular tuberculosis of hip following modern anti tubercular chemotherapy is scantly studied.[7] The present study was conducted to study cases of tuberculosis of hips in childrens.

In this study, out of 12 patients, males were 5 and females were 7. We found that right side was involved in 8 cases and left side was seen in 4 cases. Similar results were seen in study by Campbel.[8]

We found that radio graphically, 3 were normal, 4 were travelling, 2 were dislocating and 1 was atrophic. Post-treatment findings were normal in 7 cases, atrophic in 1 case, protrusion acetabuli in 1 case, perthes in 1 case and mortar pestle in 2 cases. This is in agreement with Powel et al.[9] We found that result was excellent in 40%, good in 22%, fair in 27% and poor in 11% of cases.

In making a diagnosis the authors depended more on the clinical features, classical laboratory data, study of aspirates, histological and imaging findings, because the conventional culture for tubercle bacilli was a very tedious process, and delayed the treatment.

Also, modern molecular diagnostic techniques such as PCR and ex-vivo interferon-γ test were not available till 1990. The accuracy of the clinical diagnosis was confirmed by the chemotherapy results.[10]

In the last three decades there has been a remarkable advances in the diagnosis and management. All efforts were made to preserve the hip anatomy, joint mobility and growth plates of the femoral head and tri-radiate cartilage until maturity by avoiding the conventional clean radical debridement surgery. It is known that during the early stage the disease is predominantly synovial, and that adequate treatment could prevent damage to the joint cartilage and underlying bone and thereby preserve joint function, particularly in children. Campbell and Hoffman demonstrated that Shanmugasundaram radiological appearance of the hip at presentation accurately predicts the final outcome. However, later series by Moon et al.[11], have shown that disease healing and residual pain did not correlate with the radiological stage.

CONCLUSION

Tuberculosis of hip is not uncommon among children. Clinical and radiological diagnosis along with histopathological findings is sufficient to reach the final diagnosis.

REFERENCES

1. Babhulkar S, Pande S. Tuberculosis of the hip. Clin Orthop Relat Res. 2002; 398:93–9.
2. Smith LD. Tuberculosis of the hip in children. A review of terminal results at Canton. J Bone Joint Surg 1926; 8:636-42.
3. Barr JS. Tuberculosis of the hip in children. J Am Med Assoc 1936; 10:1517-22
4. Spiegel DA, Singh GK, Banskota AK. Tuberculosis of the musculoskeletal system. Tech Orthop 2005; 20:167-78.
5. Shanmugasundaram TK. Bone and Joint Tuberculosis. Madras: Kothandaram and Co. 1983.
6. Yu HI. Tuberculosis of the hip; a followup study of 58 cases with special reference to fusion results in young children. J Bone Joint Surg Am 1951; 33:131-43.
7. McCarroll HR, Heath RD. Tuberculosis of the hip in children; certain roentgenographic manifestations, secondary changes in the extremity, and some suggestions for a program of therapy. J Bone Joint Surg Am 1947; 29:889-906.
8. Campbell JA, Hoffman EB. Tuberculosis of the hip in children. J Bone Joint Surg Br 1995;77:319-26.
9. Powell DA, Hunt WG. Tuberculosis in children: An update. Adv Pediatr 2006; 53:279-322.
10. Hatcher CH, Phemister DB. The primary point of infection in tuberculosis of the hip joint. Surg Gynaecol Obstet 1937; 65:721-40.
11. Moon MS, Kim SS, Lee SR, Moon YW, Moon JL, Moon SI. Tuberculosis of hip in children: A retrospective analysis. Indian J Orthop 2012; 46:191-9.

Source of support: Nil **Conflict of interest:** None declared